

---

*Original Article*ANTERIOR LAMELLAR RECESSION VERSUS TARSAL FRACTURE FOR  
MANAGEMENT OF RECURRENT CICATRICIAL UPPER LID ENTROPION: A  
RANDOMIZED COMPARATIVE STUDY

Awny, I.

Ophthalmology dept., Faculty of Medicine, Sohag Univ., Sohag, Egypt

\*E-mail: [dr.islamophth@yahoo.com](mailto:dr.islamophth@yahoo.com)

Received 15/10/2020

Accepted 1/12/2020

---

**Abstract**

**Purpose:** to evaluate the efficacy of anterior lamellar recession procedure in the management of recurrent upper eyelid entropion. **Design:** randomized prospective comparative study. **Methods:** all cases will be operated by anterior lamellar recession or tarsal fracture technique. **Main outcome procedure:** anatomical success is defined as the lid margin is stored to its normal position and no skin touch the ocular surface. **Results:** 20 upper eyelids of 20 patients with recurrent upper eyelid entropion are randomly divided into two groups, and will have either anterior lamellar recession surgery (group A) or tarsal fracture and marginal rotation surgery (group B). In group A, anatomical success was achieved in 70 % of cases and 3 cases (30%) had recurrence. **Conclusion:** this study shows that recurrent upper eyelid entropion can be managed efficiently with anterior lamellar recession technique.

**Keywords:** *Recurrence, Entropion, Upper eyelid*

---

**1. Introduction**

Cicatricial entropion of the upper lid is caused by vertical tarsoconjunctival contracture that leads to inward rotation of the lid margin resulting in ocular irritation by the inward turning of the eyelashes or keratinized lid margin causing corneal ulcerations and opacifications [1]. One of the most common causes of cicatricial entropion of the upper eyelid is trachoma which leads to inflammation and destruction of the conjunctiva, associated with infiltration of the tarsal plate with subsequent fibrosis leading to inward rotation of the lid margin [2]. Although various surgical procedures have been described to correct this condition,

none of them offers the ultimate solution [3]. Tarsal fracture is a viable surgical option that preserves the lashes and can deliver acceptable cosmesis. 6-0 vicryl double armed sutures are placed partially through the tarsus and externalized. A full-thickness skin incision with tarsal fracture is done to direct the lid margin away from the globe. Everting sutures are placed to place to rotate the lid margin anteriorly, and the skin is closed [4]. Anterior lamellar recession (ALR) is a well-known conventional surgical method for the correction of mild to moderate upper lid entropion. It consists of splitting the

eyelid into two lamellae anterior skin and muscle lamella and posterior tarsus and conjunctiva lamella, then recessing the anterior lamella and leaving the exposed tarsus bare [5]. The aim of the study is to

## 2. Patients and Methods

This study was a randomized prospective comparative study. 20 eyes were evaluated and divided randomly according to which eye operated right or left into two groups, each group included 10 eyes, the first group was operated by anterior lamellar recession and the second group

### 2.1. Preoperative data

Data included: **1)** History taking include age, gender, and history of previous eyelid surgery. **2)** Detailed lid examination: a) Extent of involvement (generalized or

### 2.2. Surgical technique

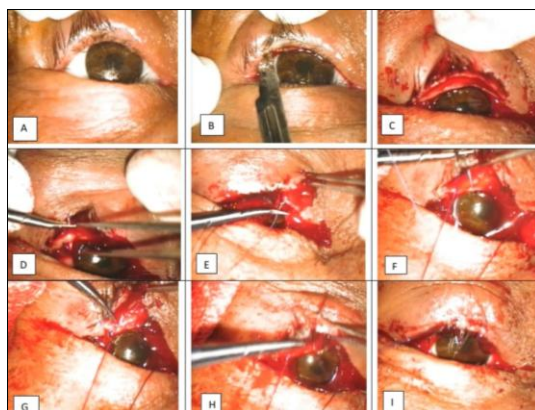
The patients were divided randomly into two groups. The first group was operated by anterior lamellar recession while the second group was operated by tarsal fracture technique. **(1) Anterior lamellar recession, fig. a)** The operation was done under local anesthesia by local infiltration of 2 % lidocaine through 1: 100,000 epinephrine. b) The eyelid margin incised along the posterior abnormal eyelash from the lateral commissure to just lateral to the lacrimal punctum. c) Then dissection is done toward the superior tarsal border. d) Trimming of the anterior lid margin including abnormal raw of lashes and keratinized tissue. e) The anterior lamella (skin and muscle flap) was then recessed and fixed to tarsus 4 mm above the lid margin with 6-0 Vicryl horizontal mattress sutures. f) Postoperative treatment with topical anti-

compare the surgical outcomes of anterior lamellar recession versus tarsal fracture in treatment of recurrent cicatricial entropion of the upper eyelid.

was operated by tarsal fracture. The study was done in Sohag University Hospital, Ophthalmology Department. **Inclusion criteria:** recurrent cicatricial Eyes with upper lid entropion with severe abnormal lid margin. **Exclusion criteria:** Non recurrent cases of cicatricial upper lid entropion.

localized). b) State of tarsal plate (existence of shrinkage or loosening). c) Any other lid abnormalities.

ibiotics and steroids ointment for 6 weeks, and systemic anti-inflammatory and antibiotics for 1 week. **(2) Tarsal fracture technique:** a) The operation was under local anesthesia by local infiltration of 2% lidocaine through 1: 100,000 epinephrine. b) Traction sutures were made by sewing 4/0 silk sutures at the lid margin. c) Full thickness skin incision was made 4 mm above the lid margin. 4) Dissection was done to expose the tarsus. e) Three double armed (Vicryl 5/0) are passed first through the lid margin behind the eyelashes then passed transversely through the distal part of the tarsus, and finally passed again through the lid margin and tied to evert the eyelid margin. f) Postoperative treatment with topical antibiotics and steroids ointment for 6 weeks, and systemic antibiotics and anti-inflammatory for 1 week.



**Figure 1.** Anterior lamellar recession technique

### 2.3. Postoperative follow up

The patients were examined one day postoperative, one week, one month, three months, and lastly six months postoperative. The success of the operations was categorized as anatomical or complete. Anatomical success was defined as disappearance of lid margin abnormality and

### 2.4. Statistical analysis

Statistical analysis was performed using Statistical Package for Social Sciences Software version 17 (SPSS Inc., Chicago, Illinois). For subgroup analyses, nominal

keratinization, appropriate localization of mucocutaneous junction, and no skin touching the ocular surface. Presence of aberrant lash did not indicate a treatment failure. Complete success was described as anatomical success without abrading the abnormal lashes.

variables were analyzed using Chi-Square test. A p value  $\leq 0.05$  was considered statistically significant.

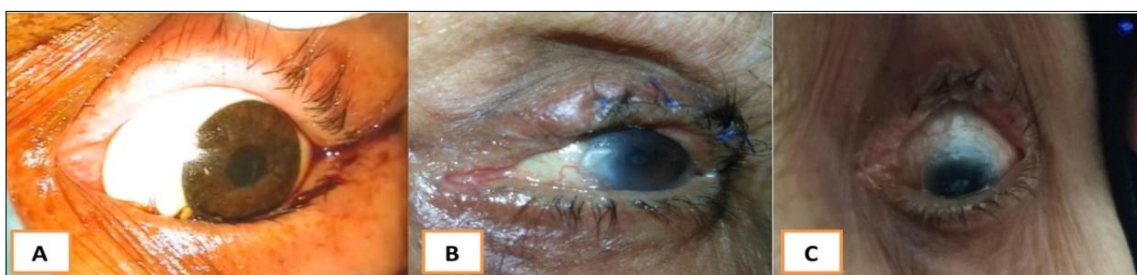
## 3. Results

20 upper eyelids of 20 patients with recurrent upper lid entropion and scarring who underwent previous entropion surgery either tarsal fracture or snellens procedure with normal tarsal consistency. These patients were 8 males (40%) and 12 females (60%). Age ranged from 45 to 80 years with an overall mean age of 62.5 years, tab. (1). These patients were randomly divided into two groups with follow up period for at least 6 months post-operative. **Group A:** 10 upper eyelids underwent anterior lamellar recession. **Group B:** 10 upper eyelids underwent tarsal fracture and marginal rotation. In group A with anterior lamellar recession showed 7 cases (70%) with anatomical success and keratinization

of the lid margin and no skin touching the ocular surface (4 of them with no aberrant lashes and 3 with aberrant lashes), fig. (2) and 3 cases (30%) with no anatomical success with skin touching the ocular surface that required another intervention, tab. (2). In group B with tarsal fracture technique showed 5 cases (50%) with anatomical success (3 with no aberrant lashes and 2 with no aberrant lashes) and 5 cases (50%) with no anatomical success and ocular irritation by the lid margin and eyelashes that required another intervention, tab. (2). In the two groups there were no post-operative complications such as lagophthalmos, pyogenic granuloma, or infection.

**Table 1.** Demographic data of studied cases

	Total cases	Group A 10 eyelids	Group B 10 eyelids
<b>Gender</b>	8 males (40%) 12 females (60%)	3 males (30%) 7 females (70%)	5 males (50%) 5 females (50%)
<b>Age</b>	45 - 80 years (62.5 years)	45 - 75 years (60 years)	46 - 80 years (63 years)



**Figure 2.** Results of anterior lamellar recession procedure

**Table 2.** Results of two techniques

	Group A	Group B
<b>Anatomical success</b>	7 Cases (70%) 4 with no aberrant lashes (57.1%) 3 with aberrant lashes (42.8%)	5 cases (50%) 3 with no aberrant lashes (60%) 2 with aberrant lashes (40%)
<b>Failure</b>	3 cases (30%)	5 cases (50%)

#### 4. Discussion

Anterior lamellar recession is an established technique for management of upper eyelid cicatricial entropion [5]. Anterior lamellar recession involves splitting of the eyelid into two lamellae from the grey line or behind the most posterior aberrant lashes, then recession of the anterior lamella 3 to 7 mm away from the lid margin. Reacher et al. carried out a randomized control trials for different surgical techniques for treatment of cicatricial upper eyelid entropion secondary to trachoma in 384 eyelids and noticed variations in success rates as: tarsal rotation (77%), tarsal advance and rotation (41%), tarsal advance (27%), eversion splinting (32%), and tarsal grooving (9%) [6,7]. This study cannot be compared to our study due to large number of samples, and various techniques used in this study. Adam et al. showed 52 eyes were operated, only 6 Pat-

ients had undergone previous upper lid surgery with resultant secondary cicatricial entropion, with anterior lamellar repositioning for 40 eyelids with 98 % of cases had normal anatomical lid position at follow up [8]. In another study, 97 eyelids (68 patients) with upper eyelid cicatricial entropion were operated with anterior lamellar recession and surgery for associated lid anomalies if needed. The results were complete success with no lashes touching the globe was achieved in 86 lids (90.5%). In this study, upper lid crease incision was performed then dissection downwards to splint the lid margin that provide meticulous dissection especially at the lid margin without losing the tissue plane or accidentally cutting through the tarsal plate [9]. In our study there was no need to do dissection from the superior lid crease, due to absence of associated lid anomalies.

#### 5. Conclusion

*this study shows that recurrent upper eyelid entropion can be managed efficiently with anterior lamellar recession technique*

#### References

1. Kemp E., Collin JR. Surgical management of upper lid entropion. *Br J Ophthalmol.* 1986; 70 (8): 575-579.
2. Mathur S. Cicatricial entropion of the upper eyelid. A modification in the operation. *Ophthalmologica.* 1966; 152: 207-211.
3. Rajak S., Collin R., Burton M. Trachomatous trichiasis and its management in endemic countries. *Surv Ophthalmol.* 2012; 57 (2): 105-135.
4. Iyengar S., Dresner S. Entropion, in: Black E., Nesi F., Calvano C., et al. (eds.) *Smith and Nesi's Ophthalmic Plastic and Reconstructive Surgery.* 3<sup>rd</sup> ed. Springer NY; 2012: pp. 311-315.
5. Elder M., Collin R. Anterior lamellar repositioning and grey line split of upper eyelid entropion in ocular cicatricial pemphigoid. *Eye.* 1996; 10 (1): 439-442.
6. Reacher M., Huber M., Canagaratnam R., et al. A trial of surgery for trichiasis of upper lid from Trachoma. *Br J Ophthalmol.* 1990; 74: 109-113.
7. Reacher M., Munoz B., Algassany A., et al. A controlled trial of surgery for tra-

- chomatous trichiasis of the upper lid. *Arch Ophthalmol.* 1992; 110: 667-674.
8. Ross A., Cannon P., Selva D. Management of upper eyelid cicatricial entropion. *Clin. Exp. Opth.* 2011; 39: 526-536.
9. Gawdat T., Kamal M., Saif A., et al. Anterior lamellar recession for management of upper eyelid cicatricial entropion and associated eyelid anomalies. *Int J Opthamol.* 2017; 10 (12): 1830-1834.